

# Amputations

## Introduction

Battle casualties who sustain amputations have the most severe extremity injuries.

- Historically, one in three patients with a major amputation (proximal to the wrist or ankle) will die, usually of exsanguination.
- Though amputations are visually dramatic, attention must be focused on the frequently associated life-threatening injuries.

**Goals for initial care are to preserve life, prepare the patient for evacuation, and leave the maximum number of options for definitive treatment.**

- The following are indications for amputation.
  - Partial or complete traumatic amputation.
  - Irreparable vascular injury or failed vascular repair with an ischemic limb.
  - Life-threatening sepsis due to severe local infection, including clostridial myonecrosis.
  - Severe soft-tissue and bony injury to the extremity precluding functional recovery.

The surgeon must balance the realistic likelihood of ultimate reconstruction of a functional extremity against the risk of death associated with attempts to preserve a limb. It is always desirable to secure the opinion of a second surgeon before amputating. The tactical situation may require amputation in cases where the limb might otherwise have been preserved.

- Battlefield amputations are unique.
  - Most commonly due to explosive munitions, with penetration and blast effects (see Chapter 1, Weapons Effects and Parachute Injuries).
  - Involve a large zone of injury with a high degree of contamination, which may affect the level of amputation and/or surgical intervention.
  - Require staged treatment with evacuation out of the combat zone prior to definitive closure.

**Amputations should be performed at the lowest viable level of soft tissues, in contrast to traditional anatomic amputation levels (eg, classic above knee (AK), below knee (BK), and so forth), to preserve as much limb as possible. A longer stump is desirable for final prosthetic fitting.**

- The **Open Length Preserving Amputation** (formerly Open Circular Amputation) procedure has two stages.
  - **Initial.** Complete the amputation at lowest possible level of bone and prepare the patient for evacuation to the next level of care.
  - **Reconstructive.** Involves final healing of the limb to obtain the optimal prosthetic stump.
  - **Final level of amputation and definitive treatment of the residual limb should occur in the stable environment of a CONUS hospital, not in the combat zone hospital.**

- All viable skin and soft tissues distal to the indicated level of bone amputation should be preserved for use in subsequent closure of the amputation stump. These tissues may be considered “Flaps of Opportunity” and can add length to the stump. This is especially true for amputations below the knee. Short tibial stumps can be saved with posteriorly based flaps because the gastrocnemius and soleus are frequently preserved following landmine injury.

To save length, any shape or form of a viable muscle or skin flap should be preserved. The lowest level may be an oblique or irregular wound, creating an oblique or irregular residual limb.

### **Technique of Amputation**

- Surgical preparation of the **entire** limb, because planes of injury may be much higher than initially evident.
- Tourniquet control is mandatory. If a tourniquet was placed in the prehospital setting for hemorrhage control, it is prepped entirely within the surgical field.
- Excise nonviable tissue.
  - Necrotic skin and subcutaneous tissue or skin without vascular support.
  - Muscle that is friable, shredded, grossly contaminated, or noncontractile. (This muscle is usually at the level of the retracted skin.)
  - Bone that is grossly contaminated or devoid of soft tissue support. Bone is transected at a level at which it has the potential for coverage. (This is usually at the level of the retracted muscle.)
- Identify and securely ligate major arteries and veins to prevent hemorrhage in transport.
- Identify nerves, apply gentle traction, and resect proximally to allow for retraction under soft tissue. Ligate the major nerves.
- Preserved muscle flaps should not be sutured, but should be held in their intended position by the dressing.
- Flaps should not be constructed at the initial surgery, to facilitate later closure.

In blast injuries, particularly landmine injuries, the blast forces drive debris proximally along fascial planes. It may be necessary to extend incisions proximally parallel to the axis of the extremity to ensure adequate surgical decontamination of the wound.

**The stump is never closed primarily.**

● **Special considerations.**

- Primary Symes (ankle disarticulation) has a high failure rate due to heel pad necrosis during transport. The wound should simply be debrided, retaining the clean hindfoot (talus and calcaneus).
- Primary knee disarticulation is problematic due to skin and tendon retraction necessitating reamputation at a higher less functional level. It is preferable to leave even a very short (1–2 cm) clean transtibial stump, even though nonfunctional, to prevent retraction.
- Fractures, when present proximal to the mangled segment, should not determine amputation level, but must be treated appropriately (cast, external fixator) to preserve maximal length.
- Plan the initial amputation solely on the qualities of the wound and surrounding tissues, never on the hope of achieving a particular level or flap pattern as a final result. The combat surgeon's goal is a thorough and complete debridement. Trying to preserve marginal tissue in the hope that a better stump can be constructed may lead to subsequent infection and a higher amputation level.

**Dressings and Prevention of Skin Retraction**

Since amputations must be left open, skin retraction is likely, causing the loss of usable limb length by making definitive closure difficult. This is particularly true of a patient who is the evacuation chain. Because of this, patients who will be evacuated should be placed in skin traction in order to leave the wound open and prevent skin retraction. Surgeons working for the International Committee of the Red Cross (ICRC) in a stable environment have successfully treated refugees by delayed primary closure. However, ICRC surgeons work in a relatively stable environment where evacuation is not a consideration for the refugee population. This situation does not apply to those in the air evacuation system.

**Skin Traction**

Ideally, skin traction should be maintained throughout the course of treatment. If evacuation times are reliably very short

(1–3 days), skin traction may be omitted. If there is the possibility of any delay, use skin traction to preserve limb length. When tactical conditions or resources are not available for application of casts, skin traction may be applied through weights off the end of the bed before and after transport.

- o Dry fine mesh gauze is loosely placed over the open wound. Preserved flaps are not suspended freely, but are held in their intended position by the dressing (Fig. 25-1).
- o Absorbent dressing is placed over the stump.
- o Tincture of benzoin is applied proximally on the skin up to 2 cm from the wound edge, but not including the preserved flap.
- o A stockinette for skin traction is applied.
- o Wrap stockinette with a figure-of-8 elastic wrap.
- o Two to six pounds of traction is applied through the stockinette / wrap. This may simply involve a weight attached via parachute cord to the stockinette. However, during transport, hanging weights are problematic and may be substituted with a light elastic such as surgical tubing or elastic exercise tubing applied through a transportation cast described below.
- o A transportation cast should be applied to prevent contracture and allow for continuous traction (Fig. 25-2).

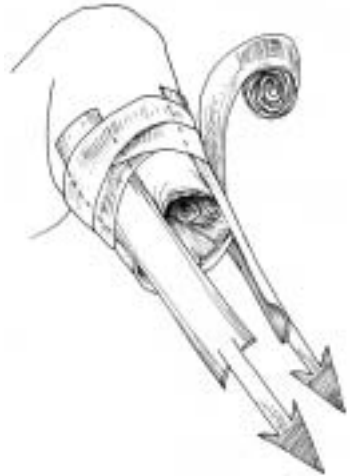

Fig. 25-1. Skin Traction

### Postoperative Management

- Prevention of contracture.
  - o BK amputations are at risk for knee flexion contractures. These contractures are preventable by using a long leg cast.

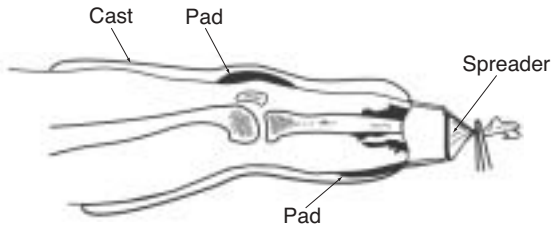


Fig. 25-2. Transportation cast allows for continuous traction.

Splinting in extension requires closer monitoring. Pillows should never support the knee, because of the increased risk of flexion contractures.

- o AK amputations are at risk for hip-flexion contractures. Prone positioning and active hip extension exercises will avoid this complication. When the casualty is supine, sandbags may be applied to the anterior distal thigh as well.
- Prevention of hemorrhage: A tourniquet should be readily available at the bedside or during transport for the first week following injury.
- Pain control: Patient comfort is paramount following amputation, particularly if dressing changes are required. Adequate analgesia should be available and the patient should be counseled regarding phantom limb pain.

### Transportation Casts

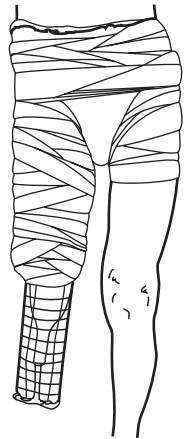
Prior to evacuation, transportation casts should be applied to maintain traction of the residual limb and support the soft tissues. The transportation cast is a well-padded cast that has integral skin traction maintained by use of an outrigger.

### Cast Application Techniques

#### Low Hip Spica cast

- Indications: Transfemoral amputation.
- Technique.
  - o Adequate anesthesia is administered and the patient is placed on the fracture table.

- o Nonviable tissue is excised, as indicated above.
  - o Stockinette or Webril is applied over lower abdomen and thigh on side of amputation. Stockinette should already be applied for skin traction.
  - o Felt padding is placed over sacrum and anterior superior iliac spine (ASIS).
  - o Towel is placed over abdomen to allow breathing space.
  - o Six-inch Webril or similar cotton batting is wrapped in 1–2 layers (Fig. 25-3).
  - o Six-inch plaster is then rolled over the Webril from the ASIS to the end of the residual limb on the affected side. Splints are applied over the posterior, lateral, and groin areas. Use a finishing roll after turning down the edges of the stockinette to give it a neat appearance.
  - o Prior to the last roll, a Cramer wire splint should be attached over the distal end of the cast to provide skin traction via the stockinette.
  - o An adequate perineal space must be left for hygiene.
  - o The towel should be removed, the cast bivalved, and a circular area over the abdomen should be cut out.
  - o Use an indelible marker to label the cast with the date of injury and surgery(ies).
- Indications: Transtibial amputations.
  - Technique.
    - o Adequate anesthesia is provided. The wound is evaluated, nonviable tissue is excised, and the wound is irrigated.
    - o Stockinette is applied to the distal end of the residual limb with tincture of Benzoin to maintain skin traction.
    - o Two to three layers of Webril are applied from the amputation to the proximal thigh.
    - o A six-inch plaster is then rolled over the thigh and leg.
    - o Prior to application of the last layer, a Cramer wire splint should be incorporated over the distal end of the residual limb. Apply skin traction when the cast is dry.



**Fig. 25-3.** Low hip spica cast.

- o Bivalve the cast.
- o Label the cast with dates of injury and surgery(ies).

### **Shoulder Spica Cast**

- Indications: Transhumeral amputation.
- Technique.
  - o Administer adequate anesthesia.
  - o Irrigate wound and excise nonviable tissue.
  - o Apply stockinette to axilla for skin traction applied with tincture of Benzoin.
  - o Wrap Webril over chest wall and around to edge of residual limb.
  - o Apply 4–6 in. plaster over the Webril.
  - o A Cramer wire splint outrigger should be applied with the last roll to allow for connection of the stockinette and application of skin traction.
  - o Label the cast with dates of injury and surgery(ies).

### **Long Arm Cast**

- Indications: Transradial amputation.
- Technique.
  - o Administer adequate anesthesia.
  - o After treatment of open wounds and application of a dressing, apply a stockinette over the distal edge of the residual limb.
  - o Apply 4-inch Webril from the residual limb to the axilla.
  - o Apply 4-inch plaster from the residual limb to the axilla.
  - o Use plaster to incorporate a Cramer wire splint over the distal edge of the residual limb in order to apply skin traction.
  - o Bivalve the cast.
  - o Label the cast with dates of injury and surgery(ies).