

Chapter 16

Thoracic Injuries

Introduction

About 15% of war injuries involve the chest. Of those, 10% are superficial (soft tissue only) requiring only basic wound treatment. The remaining 90% of chest injuries are almost all penetrating.

Those injuries involving the central column of the chest (heart, great vessels, pulmonary hilum) are generally fatal on the battlefield. Injuries of the lung parenchyma (the vast majority) can be managed by the insertion of a chest tube and basic wound treatment. Although penetrating injuries are most common, blunt chest trauma may occur and can result in disruption of the contents of the thorax as well as injury to the chest wall itself. Blast injuries can result in the rupture of air-filled structures (the lung) as well as penetrating injuries from fragments.

The immediate recognition and treatment of tension pneumothorax is the single most important and life-saving intervention in the treatment of chest injuries in combat. Distended neck veins, tracheal shift, decreased breath sounds, and hyperresonance in the affected hemithorax, and hypotension are the cardinal signs. None or all may be present. Immediate decompression is lifesaving.

With the advent of body armor, it is hoped that the majority of thoracic injuries seen in past conflicts will be avoided. Unfortunately, there will be individuals who will not have such protection, as well as others who will sustain chest injuries despite protection.

Anatomic Considerations

- Superior border is at the level of the clavicles anteriorly and the junction of the C7-T1 vertebral bodies posteriorly. The thoracic inlet at that level contains major arteries (common carotids, vertebrals), veins (anterior and internal jugulars), trachea, esophagus, and spinal cord.
- Within or traversing the container of the chest itself are found the heart and coronary vessels, great vessels including arteries (aorta, arch, innominate, right subclavian, common carotid, left subclavian, and descending aorta), veins (superior and inferior vena cava, azygous vein, brachiocephalic vein), pulmonary arteries and veins, distal trachea and main stem bronchi, lungs, and esophagus.
- The inferior border is described by the diaphragm, attached anteriorly at the T6 level and gradually sloping posteriorly to the T12 level.

Penetrating thoracic injuries below the T4 level (nipple line) have a high probability of involving abdominal structures (Fig. 16-1).

Evaluation and Diagnosis

Knowledge of the mechanism of injury (eg, blast, fragment, among others) may increase the index of suspicion for a particular injury. A complete and accurate diagnosis is usually not possible because of the limited diagnostic tools available in the setting of combat trauma. Nonetheless, because injuries to the chest can profoundly affect breathing and circulation (and on rare occasion, the airway), a complete and rapid assessment of each injury is mandatory.

- If the casualty is able to talk, there is reasonable assurance that the airway is intact.

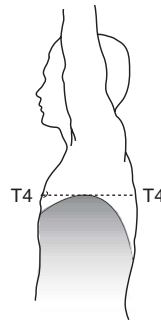


Fig. 16-1. Thoracic incision of abdominal contents.

Life-Threatening Injuries

Injuries not immediately obvious, yet requiring urgent attention, include tension pneumothorax, massive hemothorax, and cardiac tamponade.

- **Tension Pneumothorax.**
 - A patient with a known chest injury presenting with an open airway and difficulty breathing has a tension pneumothorax until proven otherwise and requires rapid decompression and the insertion of a chest tube.
- **Massive Hemothorax.**
 - The return of blood may indicate a significant intrathoracic injury. Generally, the **immediate return of 1,500 cc of blood mandates thoracotomy** (especially if the wound was sustained within the past hour). With less blood initially, but a continued loss of **200 cc/hour for over 4 hours**, thoracotomy is indicated.
 - Casualties with massive thoracic hemorrhage require damage control techniques (see Chapter 12, Damage Control Surgery).
- **Cardiac Tamponade.**
 - Distended neck veins (may be absent with significant blood loss) in the presence of clear breath sounds and hypotension indicate the possibility of life-threatening cardiac tamponade.
 - Fluid resuscitation may temporarily stabilize a patient in tamponade.
 - Perform an ultrasound (US) with a **stable** patient.
 - ◆ If **positive**, proceed to the OR (pericardial window, sternotomy, thoracotomy). Any pericardial blood mandates median sternotomy/thoracotomy.
 - ◆ A **negative** US requires either repeat US or pericardial window, depending on level of clinical suspicion.
 - Pericardiocentesis is only a stopgap measure on the way to definitive surgical repair.

- **Open pneumothorax** (hole in chest wall) is treated by placing a chest tube and sealing the hole. Alternatives include one-way valve chest dressings or a square piece of plastic dressing taped to the chest on three sides.
- **Flail chest** (entire segment of the chest wall floating due to fractures of a block of ribs, with two fractures on each rib) will require treatment (either airway intubation or observation) based on the severity of the underlying lung injury. In cases where intubation is not required, repeated intercostal nerve blocks with a long-acting local anesthetic such as Marcaine may be very helpful in relieving pain and limiting atelectasis and other pulmonary complications.

Surgical Management

Most penetrating chest injuries reaching medical attention are adequately treated with tube thoracostomy (chest tube) alone.

Tube thoracostomy (chest tube).

- Indications.
 - Known or suspected tension pneumothorax.
 - Pneumothorax (including open).
 - Hemothorax.
 - Any penetrating chest injury requiring transport (mandatory in case of aeromedical evacuation).
- Procedure (Fig. 16-2).
 - In cases of tension pneumothorax, **immediate decompression with a large bore needle is lifesaving.** An IV catheter (14/16/18 gauge at least 2–3 inches in length) is inserted in the midclavicular line in the second interspace (approximately 2 fingerbreadths below the clavicle on the adult male). Entry is confirmed by the sound of air passing through the catheter. **This must be rapidly followed by the insertion of a chest tube.**
 - In a contaminated environment, a single gram of IV cefazolin (Ancef) is recommended.
 - If time allows, prep the anterior and lateral chest on the affected side with povidone-iodine.

- o Identify the incision site along the anterior axillary line, intersecting the 5th or 6th rib.
- o Inject a local anesthetic in the awake patient, if conditions allow.
- o Make a transverse incision, 3–4 cm in length, along and centered over the rib, carrying it down to the bone.

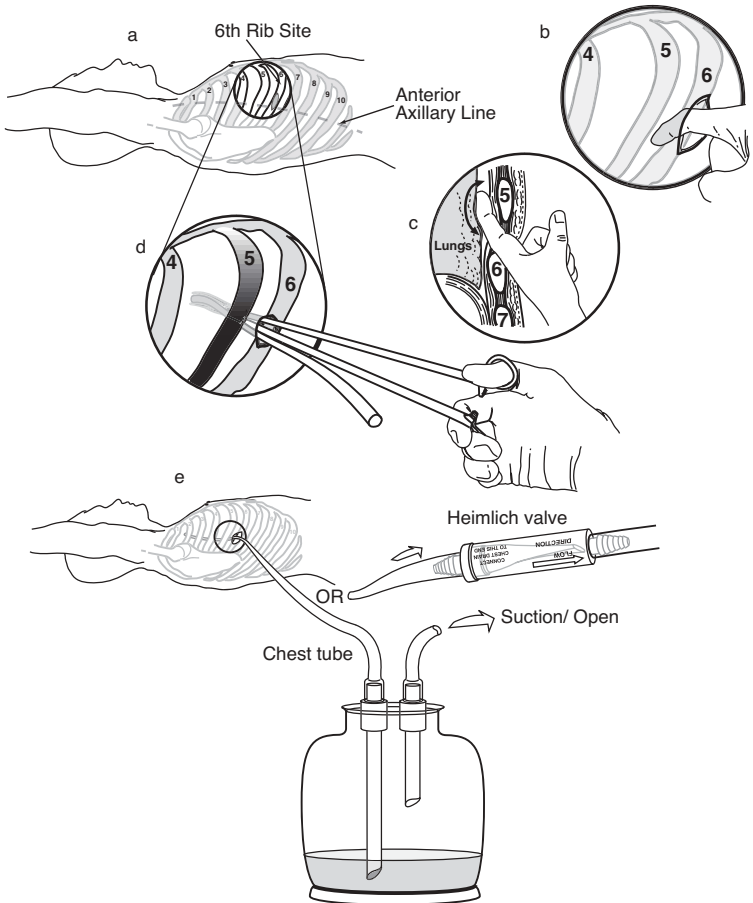


Fig. 16-2. Procedure for tube thoracostomy.

- o Insert a curved clamp in the incision, directed over the top of the rib, and push into the chest through the pleura. A distinct pop is encountered when entering the chest and a moderate amount of force is necessary to achieve this entry. A rush of air out of the chest will confirm a tension pneumothorax. Insertion depth of the tip of the clamp should be limited by the surgeon's hand to only 3 or 4 cm to make sure that the clamp does not travel deeper into the chest, resulting in damage to underlying structures.
- o Spread the clamp gently and remove. The operator's finger is then inserted to confirm entry.
- o Insert a chest tube (24 to 36 French) into the hole. All chest tube side-holes must be in the chest. If no chest tubes are available, an adult endotracheal tube may be used.
- o Attach a chest tube to a Heimlich valve, sealed pleurovac, or bottles. In a resource constrained environment, a cut-off glove or Penrose drain may be attached to the end of the chest tube.
- o Secure the tube with suture, if possible, and dress to prevent contamination.

Resuscitative Thoracotomy

- **Only indicated in penetrating chest injury in extremis or with recent loss of vital signs.**
- **These patients are generally unsalvageable, even with unlimited resources and no other significant casualties.**
- **If performed, a rapid assessment of injuries should be made, and in the case of unsalvageable injuries, the procedure should be immediately terminated.**

Procedure

- With the patient supine, make an incision in the left inframammary fold starting at the lateral border of the sternum extending to the midaxillary line (Fig. 16-3).
- The procedure should be abandoned upon the discovery of devastating injuries to the heart and great vessels.

- If no injury is found in left chest, rapidly extend the incision across the midline, crossing through the sternum with a Lebsche sternum knife, performing a mirror-image thoracotomy (clamshell, Fig. 16-4). When doing this procedure you will cut across both internal mammary arteries, which will be a significant source of bleeding.
- Elevating the anterior chest wall will expose virtually all mediastinal structures.
- Open the pericardium and assess the heart.
- **Priorities are to stop bleeding and restore central perfusion.**
 - Holes in the heart and/or great vessels should be temporarily occluded.
 - ◆ Temporary occlusion can be achieved with fingers, side-biting clamps or Foley catheters with 30 cc balloons. Any other sterile device of opportunity is acceptable.
 - Major pulmonary hilar injuries should be cross-clamped en masse.
 - Descending aorta located, cross-clamped, and cardiac function restored via defibrillation or massage. (Make sure to open the mediastinal pleura over the aorta to securely apply the vascular clamp.)
 - If unable to restore cardiac function rapidly, abandon the operation.
- With successful restoration of cardiac function, injuries should be more definitively repaired.

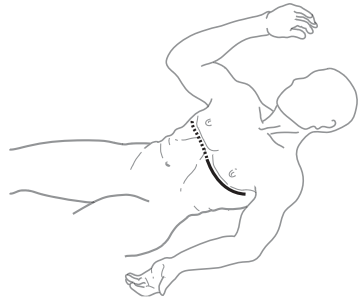

Fig. 16-3. Incision for resuscitative thoracotomy.

Subxiphoid Pericardial Window

Subxiphoid pericardial window should not be attempted in an unstable patient. Unstable patients with penetrating injuries suspicious for cardiac injury should undergo immediate median sternotomy/thoracotomy.

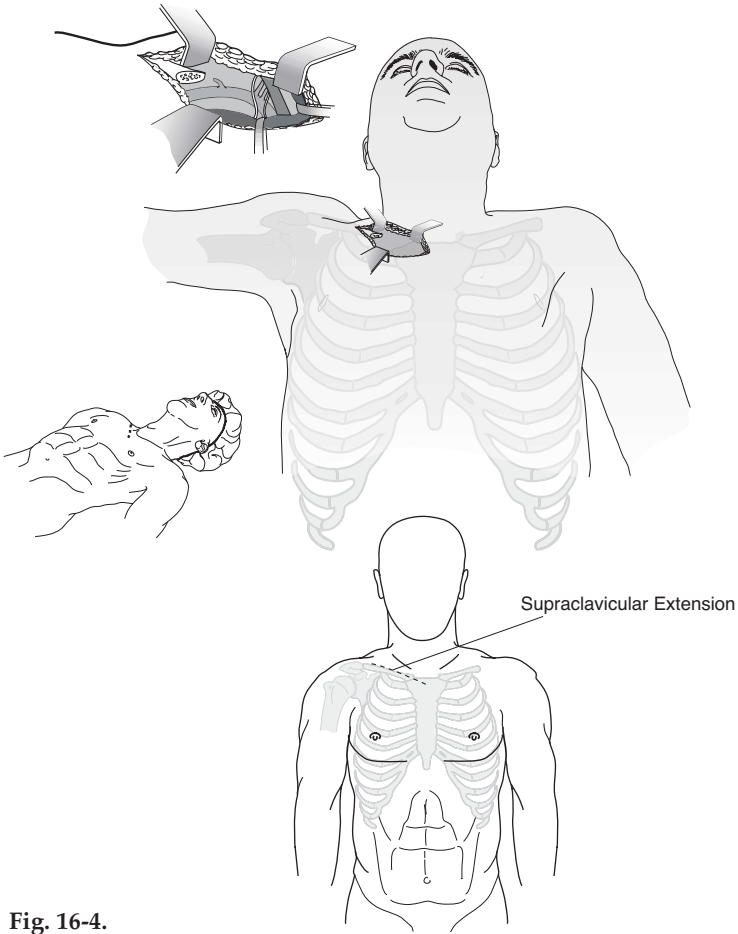


Fig. 16-4.
Supraclavicular approach.

Procedure

- With the patient supine, make a 4–5 cm longitudinal incision just on and below the xiphoid process through the skin and fascia.
- Bluntly dissect superiorly toward the heart exposing the phrenopericardial membrane below the heart.

- Place two stay sutures into the membrane and sharply incise between them, with care to avoid the heart, opening the pericardial sac and exposing the underlying beating heart.

Median Sternotomy

- Indications.
 - Suspected cardiac injury in an unstable patient.
 - Positive pericardiocentesis/subxiphoid pericardial window.
 - Suspected injury to the great vessels in the chest.
 - Suspected distal tracheal injury.
- Procedure.
 - In the supine position, make a midline skin incision from the sternal notch to just below the xiphoid.
 - Through blunt/sharp dissection, develop a plane for several centimeters both superiorly and inferiorly beneath the sternum.
 - Divide the sternum with a sternal saw or Lebsche knife. Keep the foot of the knife/saw tilted up toward the undersurface of the sternum to avoid cardiac injury. Bone wax can be used to decrease bleeding on the cut edges of the sternum.
 - Separate the halves of the sternum using a chest retractor.
 - Carefully divide the pericardium superiorly, avoiding the innominate vein, exposing the heart and base of the great vessels.

In general, exposure to the heart and great vessels is best achieved through a median sternotomy. For proximal left subclavian artery injuries, additional exposure (trap door) may be necessary.

- Close with wire suture directly through the halves of the sternum, approximately 2 cm from the edge, or around the sternum through the costal interspaces using wire sutures.
- Place one or two mediastinal tubes for drainage, exiting through a midline stab wound inferior to the mediastinal skin incision.

Other Approaches

● **Supraclavicular.**

- Indication.
 - ◆ Mid to distal subclavian artery injury.
- Procedure.
 - ◆ Make an incision 2 cm above and parallel to the clavicle, beginning at the sternal notch and extending laterally 8 cm.

● **Trap door (Fig. 16-5).**

- Indication.
 - ◆ Proximal left subclavian artery injury.
- Procedure.

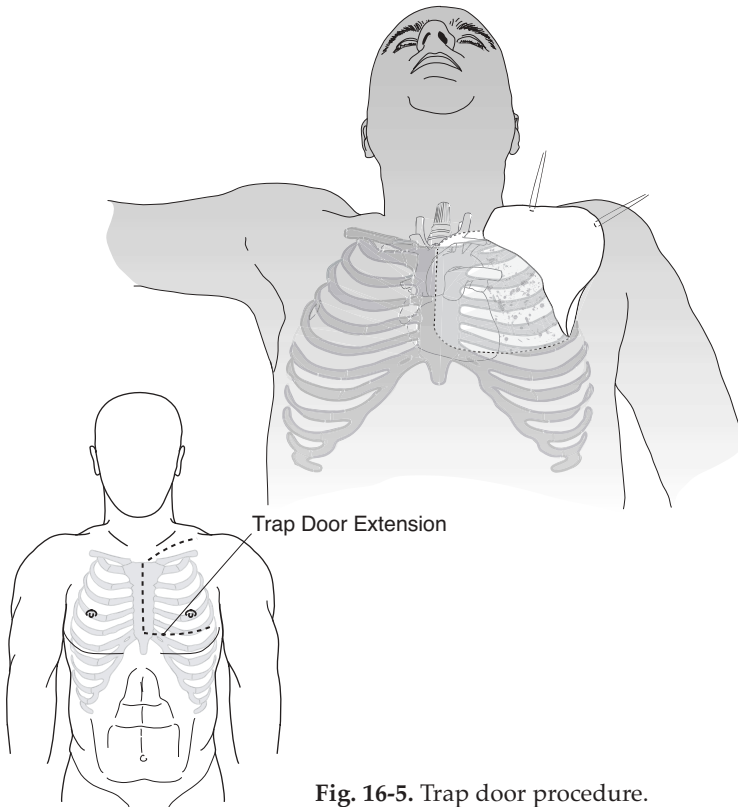


Fig. 16-5. Trap door procedure.

- ◆ Perform supraclavicular approach as above.
- ◆ Perform a partial median sternotomy to the fourth intercostal space.
- ◆ At the fourth intercostal interspace, incise the skin laterally in the submammary fold to the anterior axillary line.
- ◆ Divide the sternum laterally and continue in the 4th intercostal space (ICS) to the anterior axillary line. The internal mammary artery will be divided and must be controlled.
- ◆ It may be necessary to either fracture or remove a section of clavicle to gain adequate exposure of the proximal left subclavian artery.
- ◆ Approach distal left subclavian artery injuries through a supraclavicular incision.
- **Thoracoabdominal.**
 - Indication.
 - ◆ Combined thoracic and abdominal injuries.
 - Procedure.
 - ◆ The resuscitative thoracotomy can be continued medially and inferiorly across the costal margin into the abdominal midline to complete a thoracoabdominal incision.
 - ◆ Alternatively, a separate abdominal incision can be made.
 - ◆ With right-sided lower chest injuries, the liver and retrohepatic vena cava can be exposed well using a right thoracoabdominal approach.

Specific Injuries

- **Vascular.**
 - Initially, holes in vessels should be digitally occluded. Stopgap measures include placing Fogarty or Foley catheters, side-biting clamps, or in the case of venous injuries, sponge sticks.
 - Total occlusion or clamping may temporarily be necessary to allow resuscitation to continue and restore cardiac function.

- o If cardiac function cannot be restored within 5 to 10 minutes, the procedure should be abandoned (on-the-table triage).
- o Repair of vessels should follow the principles detailed in vascular repair: attempting primary repair if possible, with the use of prosthetics if primary repair is not feasible. Consider shunting as an alternative.

● **Heart.**

The usual result of high-velocity injuries to the heart is irreparable destruction of the muscle.

- o Isolated punctures of the heart should be exposed (opening the pericardium) and occluded by finger pressure. Other methods include the use of a Foley catheter or skin staples.
- o Use pledgeted horizontal mattress sutures (2-0 prolene) on a tapered needle for definitive repair. **Care must be taken to avoid additional injury to coronary vessels.** Extreme care must be taken to avoid tearing the cardiac muscle.
- o Atrial repairs may include simple ligature, stapled repair, or running closures (Fig. 16-6).
- o Temporary inflow occlusion may prove helpful in repair.
- o More complex repairs are impractical without cardiac bypass.

● **Lung.**

- o **Tube thoracostomy alone is adequate treatment for most simple lung parenchymal injuries.**
- o **Large air leaks not responding to chest tubes** or that do not allow adequate ventilation will require open repair (see tracheobronchial tree below).
- o **Posterolateral thoracotomy is preferred for isolated lung injuries.** Anterior thoracotomy may also be used.
- o Control simple bleeding with absorbable suture on a tapered needle. Alternatively, staples (TA-90) may be used for bleeding lung tears.

- o **Tractotomy:** Open any bleeding tracts (through and through lung penetrations) with a GIA stapler and ligate bleeding points.

Do not simply close the entrance and exit points of penetrating tracts in the lung. With positive pressure ventilation, the risk is air embolism. The more central the injury, the higher the risk.

- o Resection for bleeding may be indicated with severe parenchymal injury. Anatomic resections are **not** indicated and simple stapled wedge excisions recommended.
- o Uncontrolled parenchymal/hilar bleeding, or complex hilar injuries with massive air leak should be controlled with hilar clamping and repair attempted. Pneumonectomy is performed as a last resort (90% mortality).

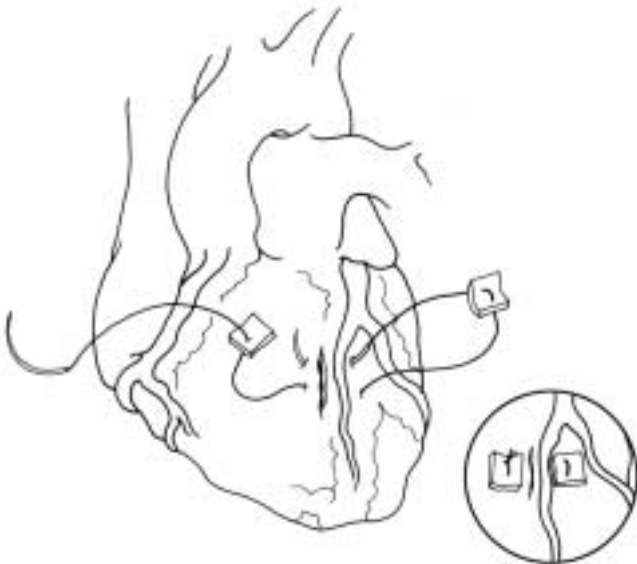

Fig. 16-6. Repair of penetrating cardiac injury.

● **Tracheobronchial tree.**

- Suspect the diagnosis with massive air leak, frothy hemoptysis, and pneumomediastinum.
- Confirm by bronchoscopy.
- Airway control is paramount.
- Median sternotomy is best approach.
- Repair over endotracheal tube with absorbable suture — may require segmental resection. Bolster with pleural or intercostal muscle flap.
- Temporizing measures include:
 - ◆ Single lung ventilation.
 - ◆ Control the airway through the defect.

● **Esophagus.**

- Isolated thoracic esophageal injuries are exceedingly rare. They will usually be diagnosed incidentally associated with other intrathoracic injuries.
- Diagnostic clues include pain, fever, leucocytosis, cervical emphysema, Hamman's sign, chest X-ray (CXR) evidence of pneumothorax, mediastinal air, and pleural effusion. Contrast swallow may confirm the diagnosis.
- Start IV antibiotics as soon as the diagnosis is suspected, and continue post-op until fever and leucocytosis resolve. This is an adjunctive measure only. **Surgery is the definitive treatment.**
- For stable patients in a forward location, chest tube drainage and a nasogastric tube placed above the level of injury is a temporizing measure. Ideally, primary repair is performed within 6–12 hours of injury. Beyond 12 hours, isolation of the injured segment may be necessary.

The preferred approach for intrathoracic esophageal injuries is posterolateral thoracotomy; right for upper esophagus and left for lower esophagus.

- Locate the injury by mobilizing the esophagus. Primarily repair with a single layer of 3-0 absorbable suture and cover with pleural or intercostal muscle flap.

- o Drainage with chest tubes (one apical, one posterior) is recommended.
 - o If unable to primarily repair (as with a large segmental loss or severely contaminated/old injury), staple above and below the injury, place a nasogastric (NG) tube into the upper pouch and place a gastrostomy tube into the stomach. Drain the chest as indicated above. Complex exclusion procedures are not indicated in a forward operative setting.
 - o An alternative when the esophageal injury is too old for primary repair is to close the injury over a large T-tube, which converts the injury to a controlled fistula. The mediastinum is then widely drained using chest tubes or closed suction catheters placed nearby. After a mature fistula tract is established, slowly advance the T-tube and later the mediastinal drains can be slowly advanced.
- **Diaphragm.**
 - o All injuries of the diaphragm should be closed.
 - ◆ Simple small lacerations (< 2 cm) should be reapproximated with interrupted nonabsorbable 0 or 1-0 horizontal mattress sutures.
 - ◆ Lacerations larger than 2 cm should be approximated as above, then reinforced with a running suture to assure an airtight closure.
 - ◆ Care should be exercised in the central tendon area to avoid inadvertent cardiac injury during the repair.
 - o If there is significant contamination of the pleural space by associated enteral injuries, anterior thoracotomy and pleural irrigation and drainage with two well-placed chest tubes should strongly be considered.
 - ◆ Inadequate irrigation and drainage leads to a high incidence of empyema, especially of the fungal variety.

